



A case of Intracapsular Femoral Neck Fracture with degloving injury of thigh in a 6 year old girl.

Author:- Dr. Archan Desai, Dr. Madhav Khadilkar, Bharati Hospital And Research Center, Pune.

Introduction

Femoral neck fractures account for less than 1 % of all fractures in pediatric age group and mostly attributed to High energy trauma(85-90%) - fall from height or road traffic accident. [1,2]

Methods & Materials

•6 years old female child with history of being runover by a truck 10 hours prior to presentation in casualty. She was hemodynamically unstable and had to be intubated. Wounds were washed, tag sutures taken and dressing done in the ICU.

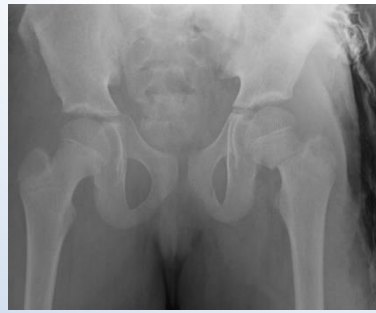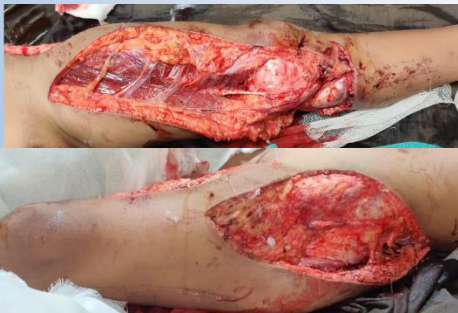•Patient was operated on the 4th day, and fixation of the # with 1 CC screw and an External fixator. The degloving injuries were debrided and sutured by plastic surgeon.

•Regular dressings were done as wounds had got infected (multibacillary). Appropriate Antibiotics were started. (Organisms: P. aeruginosa, K. pneumonia, A. baumannii ; Antibiotics : Inj. PIPTAZ, Inj. Vancomycin escalated to Inj. Colistin)

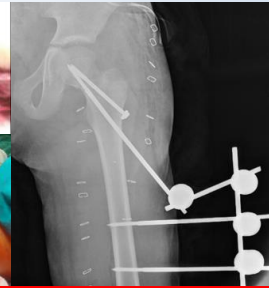
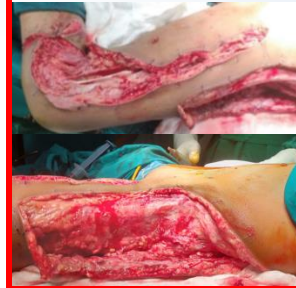•At 4 weeks Ex fix was removed and Hip Spica applied with windows for dressing. Repeated dressings of the wounds and the bedsores on the opposite side done for 3-4wks.

•Spica removed at 8 wks post op, xray taken and abduction splint applied for 2 weeks. Gradual mobilization of hip started.

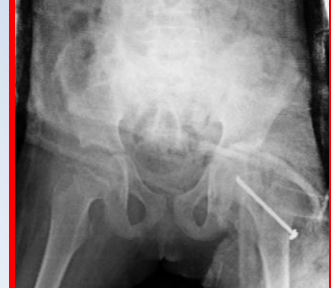Images On Presentation



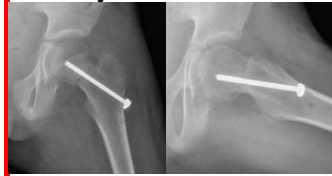Intra and Post-op



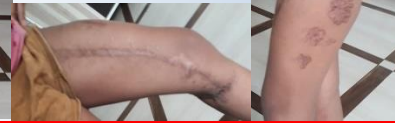Xray at 4 weeks



Xray at 8 weeks



9 -month Follow up



Results

At 10-12 wks all wounds healed. AB's stopped and patient mobilized with gradual weight bearing.

At 24 wks the patient was walking full weight bearing without support or limp with full ROM of the affected hip and knee.

Conclusion

1. Lack of immediate resuscitation led to a delay in definitive management and infection.
2. A multidisciplinary scientific approach by Orthopaedics and Plastic surgeon saved the situation and led to a good outcome.
3. External fixator is a versatile modality and can be used such difficult situations.